

- [4] García-Álvarez M, Pineda-Tenor D, Jiménez-Sousa MA, Fernández-Rodríguez A, Guzmán-Fulgencio M, Resino S. Relationship of vitamin D status with advanced liver fibrosis and response to hepatitis C virus therapy: a meta-analysis. *Hepatology* 2014;60:1541–1550.
- [5] Petta S, Cammà C, Scazzone C, Tripodo C, Di Marco V, Bono A, et al. Low vitamin D serum level is related to severe fibrosis and low responsiveness to interferon-based therapy in genotype 1 chronic hepatitis C. *Hepatology* 2010;51:1158–1167.
- [6] Lange CM, Bojunga J, Ramos-Lopez E, von Wagner M, Hassler A, Vermehren J, et al. Vitamin D deficiency and a CYP27B1-1260 promoter polymorphism are associated with chronic hepatitis C and poor response to interferon-alfa based therapy. *J Hepatol* 2011;54:887–893.
- [7] Lange CM, Bibert S, Kutalik Z, Burgisser P, Cerny A, Dufour JF, et al. A genetic validation study reveals a role of vitamin D metabolism in the response to interferon-alfa-based therapy of chronic hepatitis C. *PLoS One* 2012;7:e40159.
- [8] Grammatikos G, Lange C, Susser S, Schwendy S, Dikopoulos N, Buggisch P, et al. Vitamin D levels vary during antiviral treatment but are unable to predict treatment outcome in HCV genotype 1 infected patients. *PLoS One* 2014;9:e87974.
- [9] Kitson MT, Sarrazin C, Toniutto P, Roberts SK. Relationship between vitamin D status and response to HCV therapy. *Hepatology* 2015. <http://dx.doi.org/10.1002/hep.27797>.
- [10] Kitson MT, Roberts SK. D-livering the message: the importance of vitamin D status in chronic liver disease. *J Hepatol* 2012;57:897–909.

Matthew T. Kitson<sup>1</sup>

Christoph Sarrazin<sup>2</sup>

Pierluigi Toniutto<sup>3</sup>

Stuart Keith Roberts<sup>1,\*</sup>

<sup>1</sup>The Alfred Hospital, Department of Hepatology, Melbourne, Victoria 3004, Australia

<sup>2</sup>J.W. Goethe-University Hospital, Medizinische Klinik 1, Frankfurt 60590, Germany

<sup>3</sup>Internal Medicine, University of Udine, Department of Medical Sciences Clinical & Experimental, Udine, Italy

\*Corresponding author. Address: The Alfred Hospital, Department of Hepatology, Melbourne, Victoria 3004, Australia.

Tel.: +61 439633775; fax: +61 390762194.

E-mail address: [s.roberts@alfred.org.au](mailto:s.roberts@alfred.org.au)



CrossMark

## Hepatocyte senescence explains conjugated bilirubinaemia in chronic liver failure

To the Editor:

Conjugated bilirubinaemia in patients with chronic liver disease (CLD) reflects hepatic decompensation and a poor prognosis [1]. The pathophysiology that underlies conjugated bilirubinaemia in hepatic decompensation is poorly understood. There is no demonstrable flaw in processing unconjugated bilirubin and a more likely explanation is altered hepatocyte handling of conjugated bilirubin.

Hepatocyte senescence is present across diverse aetiologies and as many as 80% of hepatocytes show the senescent phenotype in advanced liver disease [2]. Metabolic activity is altered when a cell becomes senescent and one potential consequence is an alteration of conjugated bilirubin transport in senescent hepatocytes, which accumulate in advanced CLD.

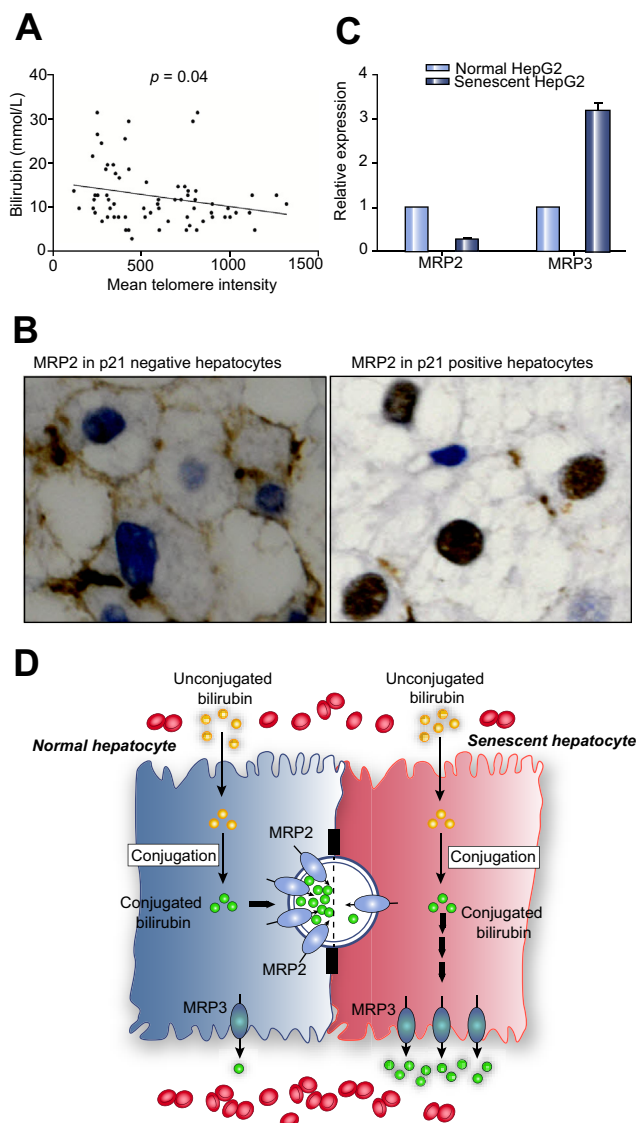
Serum bilirubin and hepatocyte telomere length were measured in 70 patients within the spectrum of NAFLD. Mean hepatocyte telomere intensity, a surrogate marker of telomere length, was measured using quantitative fluorescent *in-situ* hybridization, as described [3]. There was an inverse relationship between serum bilirubin and hepatocyte telomere length ( $p = 0.04$ , Fig. 1). Thus, accelerated hepatocyte ageing is associated with jaundice.

Liver sections from five of those patients were double-stained using unconjugated mouse monoclonal anti-p21 (Dako; concentration 1:100, heat-induced EDTA-based antigen retrieval, 20 min) and unconjugated mouse monoclonal anti-MRP2

(Merck Millipore; concentration 1:20, heat-induced citrate-based antigen retrieval, 20 min). MRP2 was negative in p21-positive (senescent) hepatocytes and was only detected in p21-negative hepatocytes (Fig. 1). Reliable immunohistochemical staining could not be achieved with available MRP3 antibodies.

An *in vitro* model was used to examine gene expression of MRP2 and MRP3 in senescent hepatocytes by real-time PCR. Cellular senescence was induced in HepG2 cells by incubation with 0.5 mM H<sub>2</sub>O<sub>2</sub> in culture medium for 60 minutes, as described [4]. Expression of MRP2 was downregulated in senescent HepG2 cells; in contrast, expression of MRP3 was upregulated (Fig. 1).

Hepatocytes are polarised cells; MRP2 is restricted to the canalicular (apical) membrane, whereas MRP3 is found only in the sinusoidal (basolateral) membrane [5]. Both MRP2 and MRP3 are unidirectional efflux pumps, which transport conjugated bilirubin into the canalicular space (bile) or the sinusoid (blood), respectively [5]. Reduced MRP2 expression in senescent hepatocytes *in vitro* and an absence of MRP2 protein in p21-positive (senescent) hepatocytes suggest reduced conjugated bilirubin transport into the biliary canaliculi. Increased MRP3 expression in senescent hepatocytes may be compensatory, increasing transport of conjugated bilirubin into the hepatic sinusoid (Fig. 1). It is, however, not clear why changes in MRP2 and MRP3 accompany hepatocyte senescence.



**Fig. 1. Hepatocyte senescence, jaundice and bilirubin transporters.** (A) Hepatocyte telomere length was associated inversely with the serum bilirubin level in 70 patients with non-alcohol related fatty liver disease. (B) Immunohistochemical double-staining showed membranous MRP2 staining in p21-negative (blue nuclei; normal) hepatocytes and a lack of MRP2 staining in p21-positive (brown nuclei; senescent) hepatocytes. (C) MRP2 expression was downregulated and MRP3 expression was upregulated in senescent HepG2 cells. (D) Uptake and conjugation of unconjugated bilirubin is unaffected in senescent hepatocytes; however, altered MRP2 and MRP3 expression in senescent hepatocytes leads to transport of conjugated bilirubin back into the sinusoid rather than the biliary canaliculi.

**Conflict of interest**

The authors declared that they do not have anything to disclose regarding funding or conflict of interest with respect to this manuscript.

**Financial support**

Addenbrooke's Charitable Trust, Cambridge, UK.

**References**

- [1] Gines P, Quintero E, Arroyo V, Teres J, Bruguera M, Rimola A, et al. Compensated cirrhosis: natural history and prognostic factors. *Hepatology* 1987;7:122–128.
- [2] Aravinthan A, Scarpini C, Tachtatzis P, Verma S, Penrhyn-Lowe S, Harvey R, et al. Hepatocyte senescence predicts progression in non-alcohol-related fatty liver disease. *J Hepatol* 2013;58:549–556.
- [3] Verma S, Tachtatzis P, Penrhyn-Lowe S, Scarpini C, Jurk D, Von Zglinicki T, et al. Sustained telomere length in hepatocytes and cholangiocytes with increasing age in normal liver. *Hepatology* 2012;56:1510–1520.
- [4] Aravinthan A, Shannon N, Heaney J, Hoare M, Marshall A, Alexander GJ. The senescent hepatocyte gene signature in chronic liver disease. *Exp Gerontol* 2014;60:37–45.
- [5] Keppler D. The roles of MRP2, MRP3, OATP1B1, and OATP1B3 in conjugated hyperbilirubinemia. *Drug Metab Dispos* 2014;42:561–565.

Aloysious D. Aravinthan  
Graeme J.M. Alexander\*

Department of Medicine, University of Cambridge, Box 156,  
Cambridge University Hospitals NHS Trust, Hills Road,  
Cambridge CB2 0QQ, UK

\*Corresponding author.  
E-mail address: [gja1000@doctors.org.uk](mailto:gja1000@doctors.org.uk)